

Bilateral Ovarian Hydatid Cysts: A Case Report and Review of Literature

Ali Bendjaballah, MD
Pr. D Jamal Benaibouche
Dr. Abdelkarim Ait Zai
Pr. Hadj Bekada

Department of General Surgery
 Bab El Oued Teaching Hospital
 Algiers, Algeria

Address for correspondence:
 Ali Bendjaballah, MD
 Department of General Surgery
 Bab El Oued Teaching Hospital
 Algiers, Algeria
 E-mail: ali_bendjaballah@yahoo.fr
 Tel: 00+213-551-764-640

ABSTRACT

Hydatid cyst (disease) is an illness caused by the cysts of *Echinococcus granulosus*. The parasite has usually “dog sheep” cycle but human becomes an accidental intermediate host.

The liver is the first organ which is most frequently affected in about 70% of cases followed by the lung in about 30% of cases. However in 20% of cases the embryo passes through the capillary systems in the liver and in the lungs, reaches the general circulation and determines the formation of unusual sites of hydatid cyst. It can occur in any organ from the brain to the soft tissues; primarily or in association with other organs. The primary involvement of pelvic organs by *Echinococcus granulosus* is extremely rare. Its prevalence among humans was determined as 9.1% in a WHO study in central Peruvian Andes.²³ In Algeria the prevalence rate of hydatid cyst is higher and the disease constitutes a big problem in public health.

KEY WORDS: Bilateral ovarian hydatid cyst, *Echinococcus granulosus*, Primary involvement, Total surgical removal.

INTRODUCTION

More than two thousand years ago human *Echinococcus granulosus* disease was described by Hippocrates with the particular term “Liver filled with water”, followed by the famous Arabian physician AL-Rahzes who wrote on hydatid cyst of the liver about one thousand years ago.¹⁴

The life cycle of the parasite was recognized by DEW et al. in 1928.¹⁵

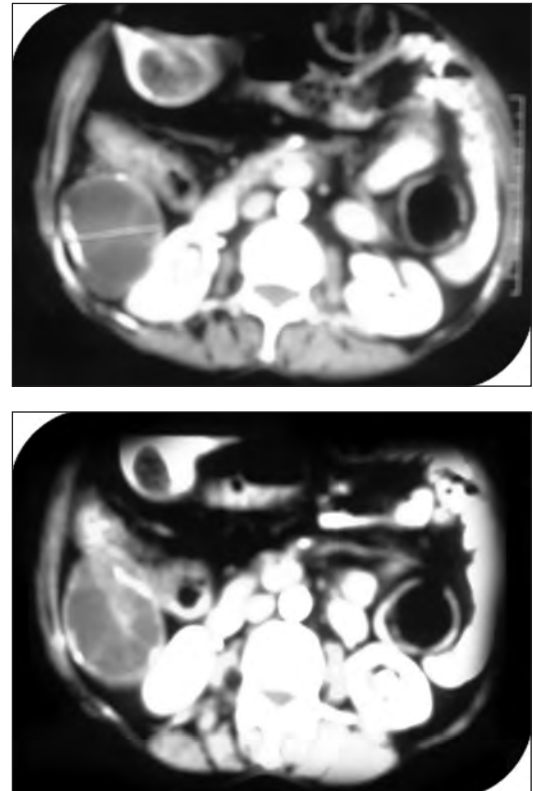


FIGURE 1 & 2. CT scan showed a calcified hydatid cyst between right lobe of liver & right kidney

Human hydatid cyst is an endemic disease and its distribution is worldwide affecting many countries in the Northern Africa as well as other parts of the world including Middle East area, India, South America, New Zealand, Australia, Turkey and Southern Europe.

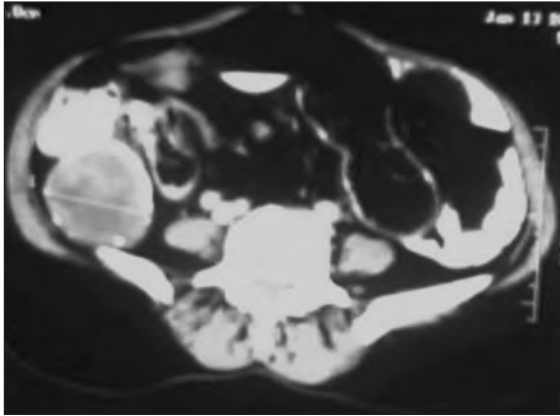


FIGURE 3. CT scan showed a calcified hydatid cyst of right para-colic gutter

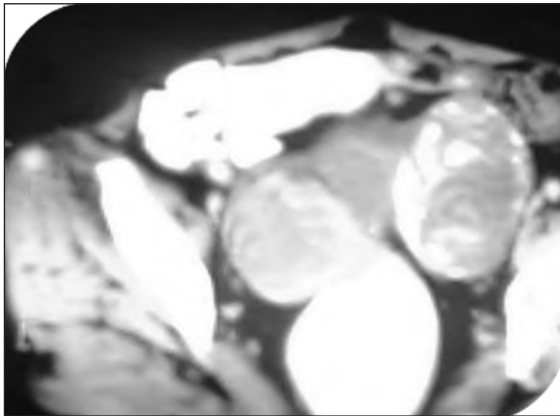
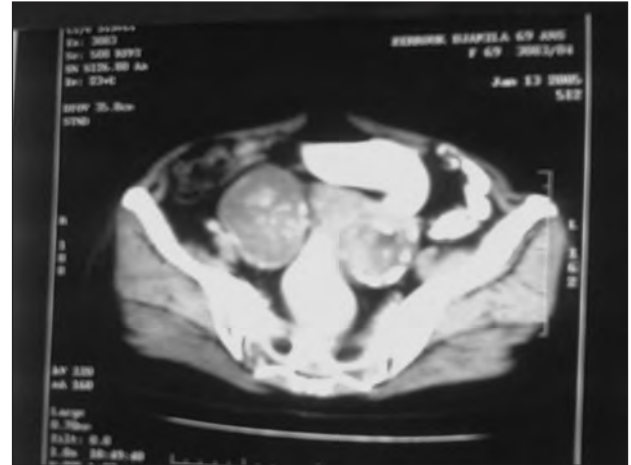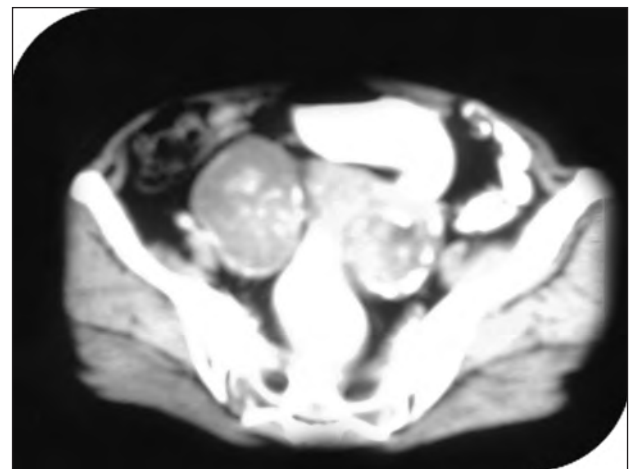


FIGURE 4. Calcified bilateral ovarian hydatid cysts



FIGURES 5. CT scan showed a calcified bilateral ovarian hydatid cyst



Primary host of hydatid disease is the dog. Humans become an accidental intermediate host; the growth is slow and it may take several years before hydatid cyst become symptomatic. Despite the plethora of publications concerning hydatid cyst, little is known about disease affecting ovaries and especially when it is primary and bilateral. We report a case of hydatid cyst of bilateral ovaries associated with two cysts of peritoneal cavity.

CASE REPORT

A 76-year-old female admitted for lower abdominal pain since several months ago; without any change in her bowel and bladder habits. She is menopause till 30 years and there is no history of previous admission to any hospital. There is no pallor, no jaundice, no fever, there is no lymphadenopathy; respiratory and cardiovascular systems examinations are normal, as well as, blood pressure and pulse.

On abdominal examination; there is no hepato and/or splenomegaly and no ascites, but two pelvic masses are palpable in the right and the left iliac region, mobile, with a smooth surface and no tender. The pervaginal and rectal examination are difficult because the patient was ashamed.

The pre-operative blood investigations are normal, chest x-ray is also normal. The ultrasonography examination showed bilateral ovarian cysts associated with another cyst between the liver and right kidney. Abdominal CT scan confirmed the findings of ultrasound examination and showed another cyst at the right para-colic gutter. There is a high suspicion of hydatid cysts. All the hydatid cysts of our patient look to be calcified.

The serology test of hydatid cyst (Indirect hem agglutination test) is done and it is highly positive "1/3500 IU."

The patient underwent laparotomy under general anesthesia and the per-operative findings were:

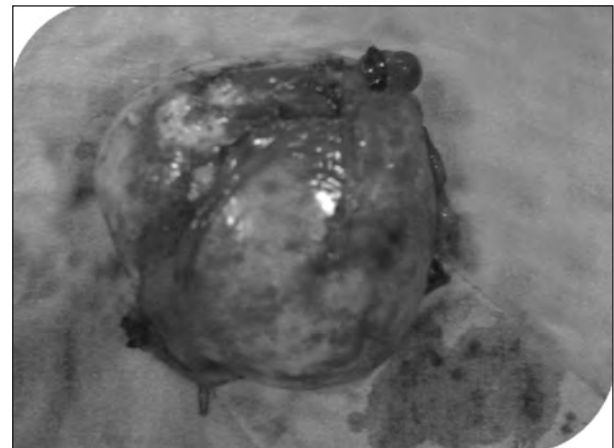
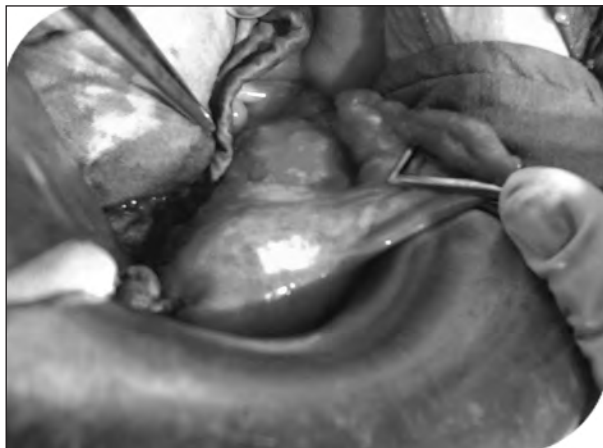
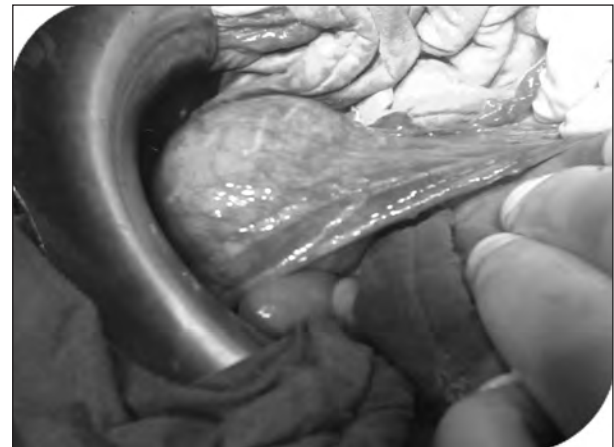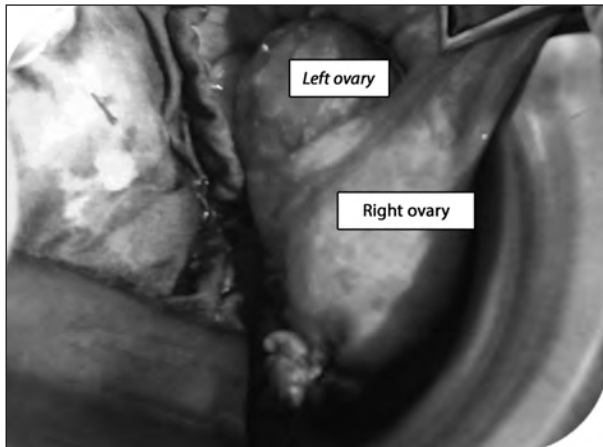


PHOTO 1 & 2. Showed bilateral ovarian hydatid cysts, the left one is deep

PHOTO 3 & 4. Hydatid cyst of right ovary totally removed

1. Two (2) cysts localized on the right and the left ovaries,
2. One (1) cyst was localized between the right kidney and the right lobe of the liver it was free from the others organs of abdominal cavity.
3. Another cyst was founded in the right para-colic gutter not attached to the caecum colon and free from the abdominal wall; it seem to be developed on the peritoneum.

There was no location of other cyst in the abdominal cavity. We protect the abdominal cavity by packing H₂O₂ soaked gauze and we use the H₂O₂ (hydrogen peroxide-10 volumes) as scolicide for at least 10 to 15mm and for the protection of the operative field. Bilateral oophorectomy was performed with total removal of the two cysts between right lobe of the liver and right kidney and the cyst of the right para-colic gutter.

The histopathology report confirmed the diagnosis of hydatid cyst. The patient passed a smooth post operative period and was discharged on the 7th post operative day in good general condition.

She was seen in outpatient department after the 2nd and 6th weeks and was doing well.

Seven years after surgery there was no evidence of any recurrence.

DISCUSSION

Algeria is one of the countries with the highest rates of *Echinococcus granulosus* and surgery for treatment of this disease constitutes about 10% of all major surgical procedures. Infestation by hydatid disease in humans occurs most commonly in the liver in about 70% of cases followed by the lung in about 30% of cases and the two organs can be affected simultaneously in about 15% of cases.⁶ The involvement of pelvic region occurs in about 0.2-2% of cases.¹

In female patients 80% of all pelvic hydatid disease involves the reproductive organs, the ovary being the most frequent location.⁷

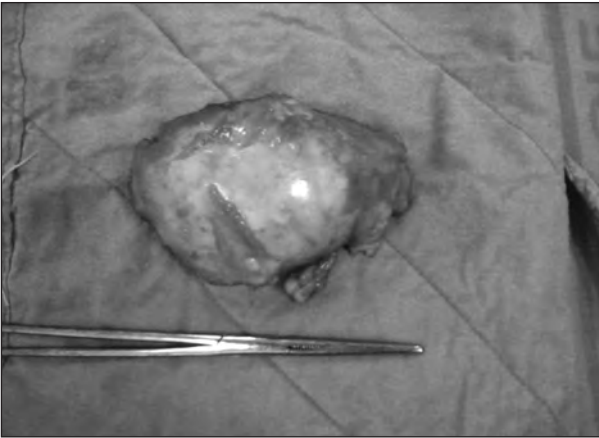
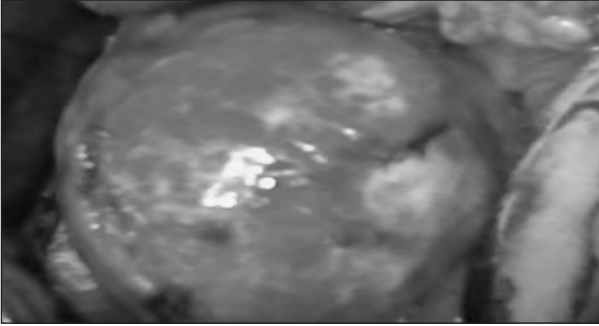


PHOTO 5 & 6. Right para colic gutter hydatid cyst which was completely removed

Primary involvement of pelvic organs by *Echinococcus granulosus* is extremely rare and is almost always secondary to rupture into the abdominal cavity of hepatic cyst or cysts from other abdominal organs.⁸ However primary pelvic *Echinococcus* has been described and the disease appears to be exclusively confined to the genital organs.⁹

Primary host of hydatid disease is the dog. Humans become an accidental intermediate host; it occurs when tapeworm ova are ingested by humans (unwashed vegetables are ingested) and often as a result of close contact with a working or pet dog and often acquired in childhood.^{3,10}

A typical hydatid cyst is formed from its embryo. It consists of three layers.¹⁷ The outer layer "pericyst or adventitia" consists of fibrous tissue is grey in color. It is formed from the host tissue as a result of chronic inflammatory reaction of the parasite. The pericyst usually increases in thickness as the cyst expands. Liver and spleen hydatid cyst have a thick pericyst, as compared to peritoneal hydatid cysts, in which the pericyst is extremely thin. In the lung and the brain there is no pericyst at all. With time, parts of pericyst may calcify and complete calcification may interrupt the nutrient and oxygen supply to the parasites and thus marks the death of the hydatid cyst. In our case the pericyst was incompletely

calcified for all the cysts. The parasite constitutes the laminated membrane (ectocyst) and the germinal layer (endocyst). The ectocyst has the appearance of the white of a hard-boiled egg. It is elastic, made up of gelatinous, chitinous material and when incised or ruptured, curls on itself, exposing the inner layer. The innermost germinal layer is cellular and consists of a number of nuclei embedded in a protoplasmic mass. It is a very thin, vital layer of the cyst and produces brood capsules with scolices, secretes hydatid fluid and forms the outer layer. The cyst fluid is crystal clear and colorless with a specific gravity of 1,005 to 1,010, is slightly alkaline and is highly antigenic and toxic; contact with fluid can give rise to anaphylactic shock.¹⁸

In our case it is most probably primary not secondary because of absence of liver or lung location with coexistence of two other hydatid cysts in the peritoneal cavity.

The pre-operative ultrasonography and CT scan examination of the abdomen were carried out to explore the lower abdominal pain and to identify the nature of the two palpable masses in the both iliac regions. These two imaging investigations (CT scan & USG) have been well established techniques in the evaluation of hydatid disease and in the follow-up.¹¹ The resolution of CT scan is very excellent in the evaluation of hydatid cyst and detecting calcifications in the cyst wall.⁵ CT scan is superior to ultrasound examination in especially defining extent of abdominal cyst.⁷

For our patient the abdominal CT scan showed calcifications of the walls of all the cysts and this finding has raised our index of suspicion of hydatid cyst.

However, other differential diagnosis was discussed in our case as well as ovarian tumors (malignant or benign); or other cysts but there were some elements which oriented our diagnosis:

- Patient came from endemic area. +++
- Ultrasound and CT scan findings: calcifications of internal wall of all hydatid cysts.
- Indirect hem agglutination test which was highly positive.
- Duration of symptomatology (several months before).

In endemic areas the possibility of hydatid disease should be considered in the differential diagnosis of any mass or growing tumor in the female pelvis.⁸ Surgical removal is the usual treatment in women with pelvic hydatid disease.²

The World Health Organization has recently outlined the treatment guidelines for hydatid cysts. Surgery is the treatment of choice for all patients with symptomatic disease and who are fit for surgery.¹⁶

The total surgical removal of all the cysts was applied for our patient and there was no spillage of cyst content at operation. In case of incomplete surgical removal or there was spillage of the cyst content in the abdominal cavity, oral medical treatment "Mebendazole or Albendazole" have proved to be quite effective in this situation and should be started in the early post operative period with a dose of 400 mg twice daily for 28 days followed by an another course of 28 days separated by 15 days of rest.^{11,4}

In our case all the cysts were completely removed and there was no spillage during operation; the medical treatment is not indicated in this case.

In Algeria therapy with Albendazole or Mebendazole is not usually prescribed by most surgeons. They feel these medications are not effective in treating hydatid cysts; and this treatment is extremely expensive.

The involvement of female genital tract in hydatid disease is extremely rare but the most important factor in its diagnosis is the awareness of the possibility of hydatid disease especially in endemic area.¹² Imaging investigations (U.S.G & CT scan) appears to be helpful for detection of unusual location of hydatid disease. Magnetic Resonance Imaging signal characteristics have also reported.¹³ Undoubtedly; the experience of the radiologist particularly in an endemic area will promote a higher index of suspicion leading to the diagnosis.⁷

Surgery is still the mainstay of treatment of hydatid cyst. Several surgical approaches from simple drainage to radical liver resection have been described for hydatid cysts. Laparoscopic interventions are usually limited to cystotomy and drainage.²⁴⁻²⁵

The laparoscopic treatment of hydatid cysts with advances and increasing experience in laparoscopic surgery, many

more attempts have made to offer the advantage of such a procedure to this patients.¹⁹ Surgery is the gold standard and primary treatment, with a variety of techniques based on the principles of eradication and elimination of recurrence while avoiding spillage.²⁰ Laparoscopic treatment of hydatid cyst liver has been increasingly popular parallel to the progress in laparoscopic surgery.²¹ However, controversies about the role of laparoscopy in the management of hepatic hydatid cyst have not been resolved, because of limited experience worldwide. These controversies included selection of patient, surgical technique and follow up.²² Laparoscopic pericystectomy combines the advantages of radical surgical resection with those of minimally invasive surgery.²⁴⁻²⁵ For good cosmetic appearance effort aiming to reduce incision of laparoscopic surgery has been thought recently. For this purpose Single Incision Laparoscopic Surgery (SILS) has gained momentum in different fields of surgical practice.²⁶⁻²⁷ For our case, the laparoscopic treatment was not well indicated and our experience was not so important and in my country the main treatment for hydatid cyst is the surgery. So now many surgical teams prefer laparoscopic approach for treating hydatid cysts.

CONCLUSION

Hydatid cysts disease is very common in North Africa especially in my country. Detection of atypical localization is made easier with Ultrasonography and CT scan examinations. Primary pelvic localization especially both ovaries are extremely rare. This disease constitutes a serious problem of public health in the endemic countries. In order to interrupt the cycle of transmission of hydatid cyst, public health measures should be implemented to eradicate the disease by the removal of infected animals. Laparoscopic treatment of hydatid cysts is now well established around the world with very good results.

REFERENCES

1. Baba A, Chaieb A, Khairi H, Keskes J. Profil epidemiologique de l'hydatidose pelvienne à propos de 15 cas. *Journal. Gynecol. Obstet. Bio. Report* ,1991; 20:657-660.
2. Okumus Y, Tayyar M, Papiroglu T, Aygen E. Uterine hydatid cyst. *Int.J. Gynaecol Obstet.* 1994; 45:51-53.
3. Gueddama F, Chemmen L, Lebbi I, Koubaa A, et al. (1990). Intra uterine hydatidosis à case report. *J Gynaecol Obstet. Biol. Report. (Paris)*; 19:725-727.
4. Fattahi SH, Dabiri RH, Baradaran H, Davachi B, Rajabzadeh F, Baharvahdat H et al. Albendazole versus placebo in treatment of echinococcosis. *Trans R Soc Trop Med Hyg.* 2001; 95:190-194.
5. Idris M, Ahmad A, Afridi SJ. Imaging spectrum of cystic echinococcosis. *Journal of Ayub Medical College* 1999; 11:10-13.
6. Kir A, Baran E. Simultaneous operation for hydatid cyst of right lung and liver. *Thoracic Cardiovascular. Surgeon.* 1995; 43:62-64.
7. Adewunmi O, Basilingappa M. Primary ovarian hydatid cyst in the K.S.A. *Saudi Medical Journal.* 2004; Vol 25(11), 1697-1700.
8. Rahman MS, Rahman J, Lysikiewicz A. Obstetric & Gynaecological presentations of hydatid disease. *Br.J. Obstet Gynaecol.* 1982; 89:665-670.
9. Azhar H. Primary echinococcal infection of the ovary. *Br.J. Obstet Gynaecol.* 1977; 84:633.
10. Ishraq DaiFalah. Hydatid cyst of the uterine cervix. *Biomed papers* 2001. 145 (2) 77-78.
11. Moussa AM, Mehrez MG, Muhtaseb SA, AL-Mudala DS, Kamel SM. Disseminated pelvic hydatidosis presenting as ovarian carcinomatosis: successful post-operative treatment with mebendazole. *Int J Gynaecol Obstet.* 1987; 25:473-478.
12. Manju A, Chhaya Rani G, Sunta J, Neelima K. An Usual Case Of Hydatid C yst Of Broad Ligament. *Journal, Indian Academy of Clinical Medecine.* 2005; Vol 6 No 1:86-87.
13. Sing S, Gibicote SV. Magnetic Resonance Imaging signal characteristics in hydatid cyst. *Austras Radiol.* 2001; 45:128-133
14. Katan YB. Intrabiliary rupture of hydatid cyst of liver. *Ann. Royal college of surgeons. England* 1977; 59:108-14.
15. Saeed Abu Eshy. Hydatid cyst associated with pregnancy: a case report and review of the literature. *Ann. of Saoudi Medecine, Vol 19 No 2, (1999).*
16. Guidelines for treatment of cystic and alveolar echinococcosis in humans. WHO Informal Working Group on Echinococcosis. *Bull World Health Organ* 1996; 74:231-42.
17. Milicevic M. Hydatid disease. In: Blumgart LH, ed. *Surgery of the Liver and Biliary Tract.* 2nd ed. New York: Churchill Livingstone; 1994:1121-50.
18. Mehra B R, Thawait A P, Gupta D O, Narang R R. Giant abdominal hydatid cyst masquerading as ovarian malignancy. *Singapore Med J.* 2007; 48(11):e284-8
19. Kedar Gorad, Neeraj Rayate, Kunal Oswal, Ashish Krishna, Avanish Deshmukh, Sarvana Rajmanickam, Shailesh Puntambekar. *Laparoscopic Removal of Pelvic Hydatid Cysts in Young Female: A Case Report* Hindawi Publishing Corporation *Minimally Invasive Surgery* Volume 2011, Article ID 346828, 3 pages.
20. Dervenis C, Delis S, Avgerinos C, Madariage J, Milicevic M. Changing concepts in the management of liver hydatid disease. *J Gastrointest Surg.* 2005; 9:869-77.
21. Ertem M, Karahasanoglu T, Yavuz N, Erguney S. Laparoscopically treated liver hydatid cysts. *Arch surg.* 2002; 137:1170-73
22. Role of laparoscopy in the management of hydatid cyst of liver. Muhammad Rafique Memon, Saleh Muhammad Channa, Bhahwal uddin Jamro. *Rawal Medical Journal: Vol. 37. No. 3, July-September 2012.*
23. Moro PL, McDonald J, Gilman RH, Silva B, Verastegui M, Malgui V, et al. Epidemiology of Echinococcus granulosus infection in central Peruvian Andes. *Bull World Health Org.* 1997; 75:553-6
24. Kopan M, Yavuz N, Kapan S, Polat S, Goksy E. Totally laparoscopic pericystectomy hepatic hydatid disease. *J.laparo endosc Adv.Surg technics.* 2004; 14:107-09
25. Khoury G; Abiad F; Geugia T; Tbout G; Jabbour S. Laparoscopic treatment of hydatid cyst of the liver and the spleen. *Surgcal endosc.* 2000; 14:243-45.
26. Barbaros U, Sumer A, Tunca F, Gozkun O, Dimerel T, Belge O, et al. Our early experiences with single incision laparoscopic surgery. The first 32 patients. *Surg. Laparoscopic endosc percutan technic.* 2010; 20:306-11
27. Cai Xiu-Jun, Zhu Zhi-Yi, Liang Xiao, Yu Hong, Wong Yi Fan, He Ji Kai. Single incision laparoscopic surgery. A case report. *China Medical Journal.* 2010; 123:269-20